



**OCEAN SURGICAL** Pty Ltd



# Implants

## Lower Posterior Teeth

### TITANIUM IMPLANTS AND LOWER POSTERIOR TOOTH REPLACEMENT

Dental implants are titanium appliances designed to replace missing teeth. They have an outer surface which integrates with alveolar jaw bone, and an inner surface into which screws and appliances can be attached to support tooth crowns and denture frameworks.

Titanium implant fixtures are a relatively modern surgical means of securing dental appliances (such as crowns, bridges and dentures) directly to your living, natural jaw bone. Based on technology used in orthopaedic surgery, titanium dental implants have similar design elements to knee or hip joint prostheses.

Only qualified, medically trained, specialist Maxillofacial surgeons have the skills and facilities to provide a comprehensive way of managing your bone, soft tissue and titanium implant needs. Surgery is provided in combination with a specially trained implant-restorative-dentist who ultimately places the final implant supported dental crown.

### WHY USE AN IMPLANT TO RETAIN YOUR DENTAL CROWN?

When you lose a tooth, complex dental movements start to occur. Firstly the teeth either side of the space start to tilt, and opposing teeth start to over-erupt. Adjacent teeth may also have restorations in them, which are no longer wedged and supported by the adjacent lost tooth. Chewing habits change, forces shift, and finally teeth with extra loads start to break, chip, crack and split; before eventually becoming lost.

Losing your first tooth is akin to the beginning of the end. Like the first fall of a domino, tooth loss starts a domino procession that can take thirty to fifty years; but which eventually leads you to having no teeth at all.

Losing a finger can be as devastating as losing an arm. Losing any part of you can be depressing, upsetting, and catastrophic.

Paradoxically, losing teeth has mixed emotions depending on who you are. For some it is a dramatic loss, but for others it means nothing at all. Some expect to lose their teeth because it is in the nature of ageing, or maybe in the genes.

If you're like us, you think teeth are a very important part of you. Teeth are needed for chewing, for smiling, and for speaking. Most importantly teeth are part of you; like fingers and arms. Losing teeth may be part of ageing, but unlike other body parts, you have the unique opportunity to get teeth back.

When you lose teeth, your dentist or dental surgeon may offer simple, short to medium-term solutions such as replacement dentures or bridge-work. These treatments are the cornerstone of restorative dentistry; and for many people are relatively immediate and cheap treatments.

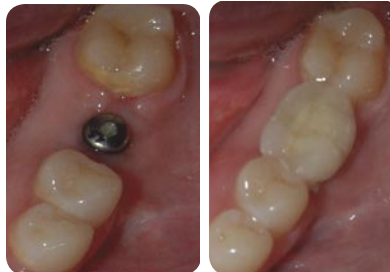Titanium implants, together with porcelain-zirconia dental restorations, offer the only real chance of a real and more permanent replacement; and are the most dynamic in being able to provide maximal aesthetics and natural function. Whilst superficially implants may appear to be the most expensive treatment option, in the long term they remain both the *cheapest biological and financial treatment-option available to you.*

Under ideal circumstances implant supported restorations can be indistinguishable from natural teeth, and have the potential to last a life-time. Only a dedicated, multi-disciplined specialist team can coordinate your care to a degree where the final product is cost-effective, clinically stable and maximally functional.

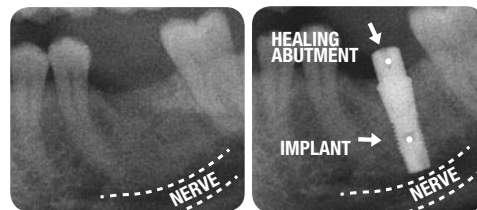
Implant supported dental crowns are not for everyone. You should carefully discuss your treatment options with your general dentist, or specialist maxillofacial surgeon. It is important that you gain as much information as possible before you embark on any treatment régime.

**Titanium dental implants offer the most conservative and long term means of maintaining a complete occlusion, whilst naturally supporting and protecting adjacent teeth from drifting, tilting or frank breakage.**

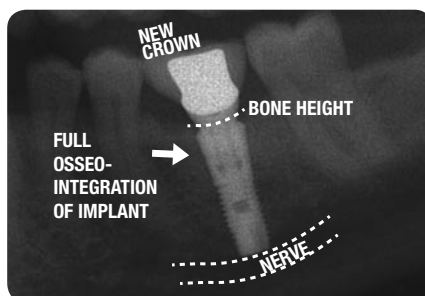
### CASE 1. 38 YEAR OLD FEMALE WITH LOSS OF ROOT CANAL TREATED LEFT LOWER FIRST MOLAR



Comparison made of site with implant healing abutment, and final zirconia-based porcelain crown fixed internally to the underlying titanium implant.

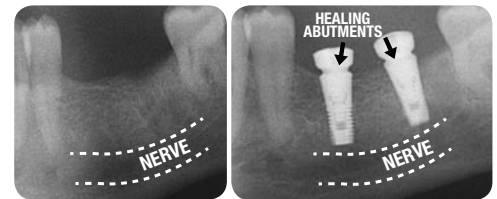


Pre- and post-operative x-rays showing fully osseointegrated collarless-titanium-implant fixture supporting internal-cone-fixed healing abutment (prior to final restoration).

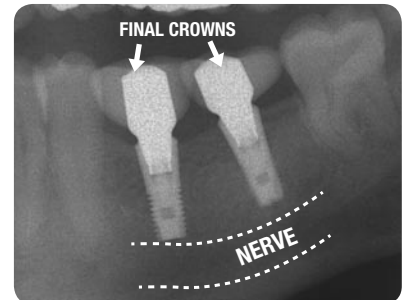


Close up of internal conical (collarless) implant supported dental restoration, showing full screw thread integration with surrounding natural living bone.

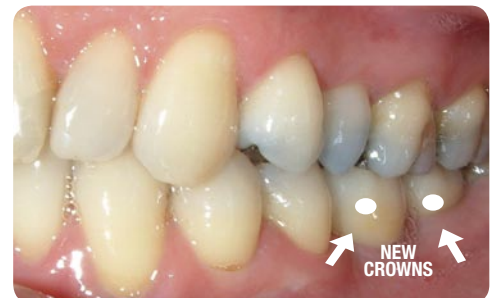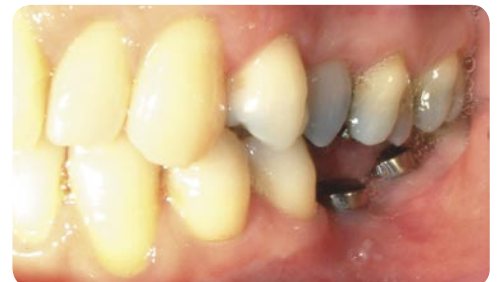### CASE 2. 47 YEAR OLD MALE WITH LOST LOWER LEFT FIRST AND SECOND MOLARS



Before and after x-rays showing 2 lower posterior implants replacing 1st and 2nd molars.

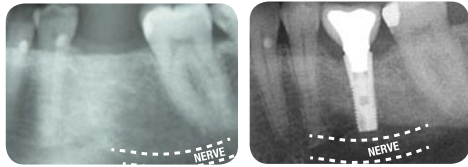


The final restoration should be a naturally blended crown, emerging from stable surrounding gum, secured to an implant platform of sufficient length and width for long term force resistance.

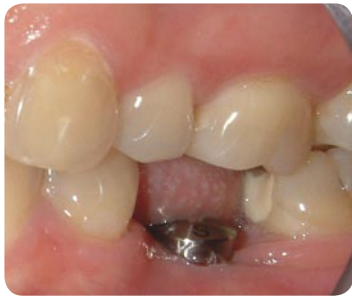

Final dental crowns provide a full and blended restoration of the original occlusal length, whilst providing lateral fullness to the missing dental arch.

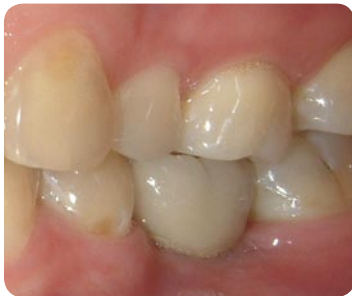**CASE 3. 35 YEAR OLD FEMALE WITH LOSS OF 1ST LOWER LEFT MOLAR**



Before and after x-rays showing final implant supported restoration in place.

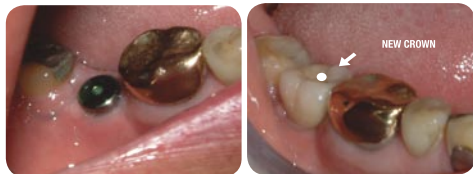

Comparison of before and after photos showing presence of healing abutment compared to final crown placement by implant-restorative dentist.

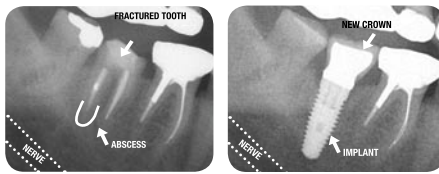

Entire treatment period (from time of implant-insertion to time of final crown-placement) spans 5 months.

**CASE 4. 60 YEAR OLD MALE WITH BROKEN DOWN 47 TOOTH REQUESTING IMPLANT REPLACEMENT**



Space behind gold-crowned tooth shows healing abutment, compared to final porcelain crown supported by internal-tri-lobe secured titanium implant. The implant supported dental crown provides occlusal protection to the forward heavily restored gold tooth.

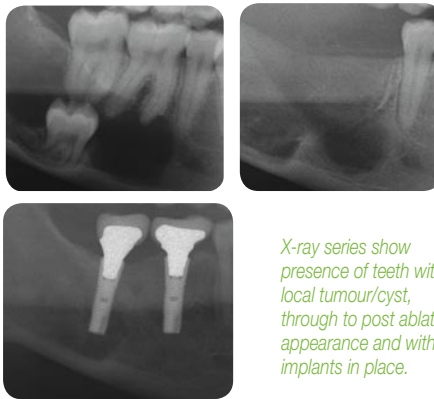


Broken down lower right 2nd molar showing failed root canal therapy, and fractured crown, leading eventually to local tooth removal by the maxillofacial surgeon (to maintain bone integrity). Post-operative x-ray shows a full osseo-integrated titanium (collared) implant fixture, supporting a zirconia-based porcelain crown.

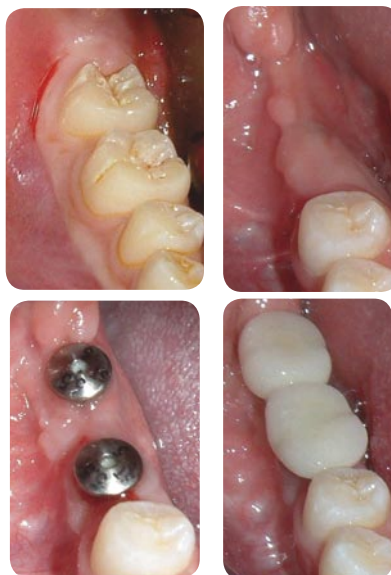Pre-operative CT scans are important to determine the position of underlying sensory nerves running through the posterior mandible (seen as a canal running obliquely at bottom left corner of both x-rays). Precise measurements of depth can be evaluated, and determinations of appropriate length and width of implants are pre-operatively predicted.

**CASE 5. 21 YEAR OLD FEMALE WITH IMPLANTS AFTER TUMOUR ABLATION**

An odontogenic keratocyst was removed in the right mandible of this lady, with loss of the impacted tooth, and first and second molars.



X-ray series show presence of teeth with local tumour/cyst, through to post ablation appearance and with final implants in place.



Picture series show original teeth lost due to surgery, with at first healing abutments (after local bone and gum grafts) with final implant crowns in place.

All surgery for ablation and reconstruction (including cyst resection, bone and gum tissue grafting, and implant replacement) are subsidised under Medicare. Crown placement is not normally covered by Medicare, but may be subsidised by dental insurance.

**ADVICE TO PATIENTS SEEKING IMPLANT TOOTH REPLACEMENT**

1. Titanium implants systems are now available which have intensive research and longitudinal experience defining high clinical reliability and precision dental restorative capacity.
2. Implant systems have maximum utility and reliability when placed by clinical teams incorporating specialist maxillofacial surgeons and especially trained implant-restorative dentists.
3. Implants may be placed at the time of tooth removal, and this maximises tissue aesthetics around the final fixed crown.
4. Because of the importance of preserving bone, it is important that your maxillofacial surgeon performs your tooth removal in a way that preserves bone form and integrity.
5. For some patients, individual clinical needs may require bone and soft tissue grafting to maximise the aesthetic, functional and temporal potential of the titanium implant supported restorations.
6. Bone and soft tissue grafting, and CT and specialist radiographic assessments are all subsidised by Medicare when provided for (or by) specialist Maxillofacial Surgeons. These costs are in addition to basic estimations of implant provision and you should carefully question the Medicare approved credentials of your providing specialist-surgical practitioner prior to embarking on any implant restorative course.
7. Implant supported restorations are not normally subsidised by Medicare except in exceptional circumstances (e.g. EPC and CLP schemes as well as reconstruction post tumour ablation).
8. Implants may be placed utilising specialist-surgical implant facilities or private hospitals, and may be combined with the use of intravenous sedation or general anaesthetic services.
9. There are many implant systems available, only a few of which are specialist-only specific. You should question your provider as to product warranties and accessibility to life-time clinical servicing.
10. With lower tooth posterior implants, there is a risk of the implant surgical process affecting the inferior dental nerve. Such surgery may lead to permanent numbness of the lower lip and/or chin on that side. Surgical risk is greatly reduced when surgery is performed by a Maxillofacial surgeon, utilising specialist CT views. Specialist assessments allow for use of implant lengths that maximally-minimise involvement of defined nerve territories.
11. You should carefully discuss the risks of lower lip and chin numbness (as with all other potential complications) with the specialist maxillofacial surgeon before embarking on any surgical or implant-restorative course.

Ocean Surgical Pty Ltd takes no responsibility for the information contained within this brochure or the accuracy of the information presented. The views expressed are the author's only, and the patient should speak directly with the surgical practitioner before embarking on any surgical course.

(c) Dr Paul Lloyd G. Coceancig, 2007. All images, words and symbols remain the property of the author. No permission for distribution or copying of this document is provided, and which remains wholly the property of Ocean Surgical Pty Ltd.

**Dr Paul Lloyd G Coceancig**  
MB ChB BDS Hons MDS OMS FRACDS OMS  
Oral and Maxillofacial Surgeon

ABN 13 103 192 187  
Phone +61 (0)2 4927 5177

Web [www.oceansurgical.com.au](http://www.oceansurgical.com.au)  
Email [manager@oceansurgical.com.au](mailto:manager@oceansurgical.com.au)

Main Office Unit 4 2nd Floor Boardwalk North  
1 Honeysuckle Drive Newcastle NSW 2300  
Postal PO Box 836 Newcastle NSW 2300